

Combined Radiology and Pathology Classification of Brain Tumors

Rozpoznanie guza mózgu na podstawie obrazu radiologicznego i patologicznego

Piotr Giedziun

Supervisor:
dr hab. inż. Henryk Maciejewski

4 March 2016



Outline

- 1 The problem
- 2 State of the art
- 3 Proposed approach
- 4 Achieved results



Definitions

Cancer

- Cancer occurs when abnormal cells grow out of control

Brain tumor

- Benign or Malignant
- Over time, a low-grade tumor can become a high-grade tumor
- Brain tumors are classified as grade I, grade II, or grade III, or grade IV



Brain tumor - Survival rate (5 years or more)

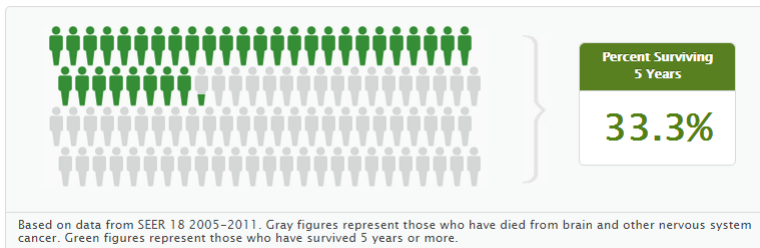

FIGURE – Based on data from SEER 18 2005-2011, cancer.gov



Brain tumor - Survival by stage

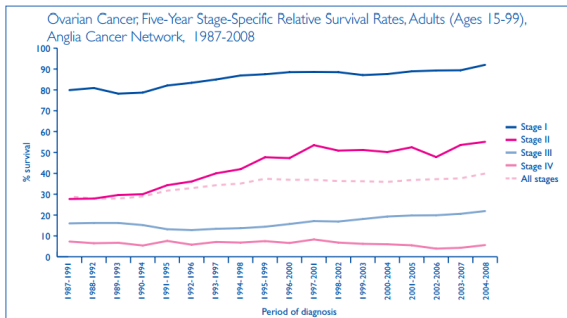
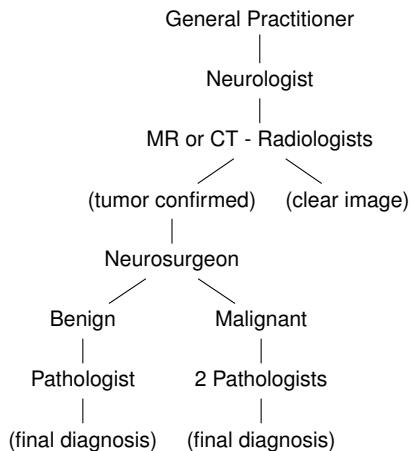


FIGURE – Ovarian cancer, Five-year stage-specific relative survival rates, adults (ages 15-99), Anglia Cancer Network, 1987-2008



Brain tumor - Diagnosis process



Diagnosis problems

Problems

- Diverse shapes, sizes and appearances of tumors
- Relies on histopathologic examination (biopsy examination)
- Waiting for tests and to start treatment
- Radiology imaging is used only to establish location, size and whether it is benign and malignant tumor

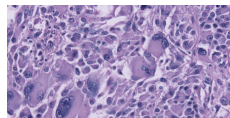


FIGURE – Glioblastoma cells

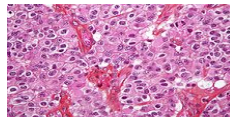


FIGURE – Oligodendroglioma cells



Diagnosis problems

Problems

- Diverse shapes, sizes and appearances of tumors
- Relies on histopathologic examination (biopsy examination)
- Waiting for tests and to start treatment
- Radiology imaging is used only to establish location, size and whether it is benign and malignant tumor

Targets in the UK

No more than 2 months wait between the date the hospital receives an urgent GP referral for suspected cancer and starting treatment

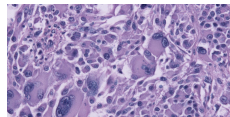


FIGURE – Glioblastoma cells

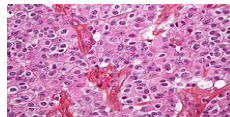


FIGURE – Oligodendroglioma cells



Aims & Limitations

Aims

- Research & build a segmentation mechanism for the MRI scans (ROI selection)
- Research & build a classifier based on the segmented radiological images
- (if possible) Combine the Pathology-based classification with radiology-based classifier

Limitations

- Limited access to the MRI samples with the diagnosis provided by the doctor
- Conservative environment - only non-black box models



Related work

Brain tumor segmentation

- The topic of brain segmentation is relatively popular thanks to BraTS challenge
- Several supervised and unsupervised algorithms were proposed
 - Random Decision Forest that classifies voxels
 - Fuzzy C-means clustering
 - Mean Shift and K-means clustering

Brain tumor classification

- Slightly less popular subject (current diagnosis fully rely on histopathology imaging)
- Feature extraction
 - Extraction of structure information
 - Feature selection
- GLCM (Gray-Level Co-occurrence Matrix)



Influential articles



Joana Festa and Sérgio Pereira and José António Mariz and Nuno Sousa and Carlos A. Silva

Automatic Brain Tumor Segmentation of Multi-sequence MR images using Random Decision Forests

Proceedings of NCI-MICCAI BRATS 2013, Nagoya, Japan, 2013



Nitish Zulpe and Vrushsen Pawar

GLCM Textural Features for Brain Tumor

International Journal of Computer Science, 2012



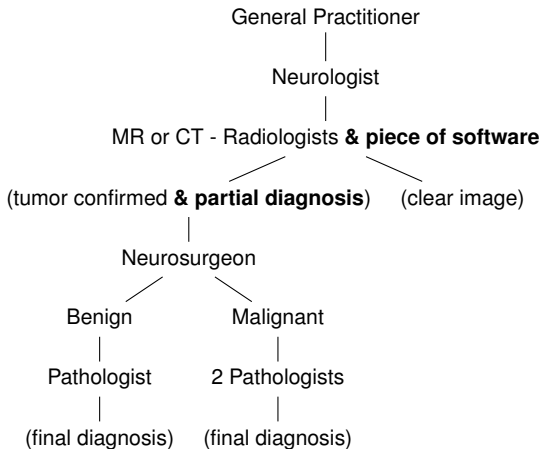
Hassan Khotanlou, Olivier Colliot, and Isabelle Bloch

Automatic brain tumor segmentation using symmetry analysis and deformable models

Nationale Superieure des Telecommunications, 2007



Brain tumor - Modified diagnosis process



Data set

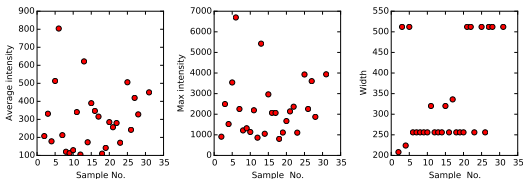


FIGURE – Plots of different attributes of the data set

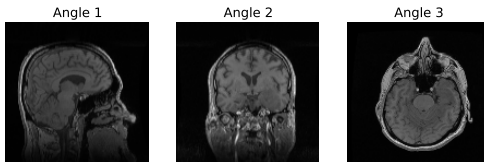


FIGURE – Viewing angles of MRI scan



Data set

Summary

- 27 cases with lower grade glioma tumors
- 13 of them with Oligodendroglioma and 14 with Astrocytoma
- Each case has 3 or 4 MRI scans (T1, T1C, FLAIR, and T2)
- Provided samples were taken using different hardware

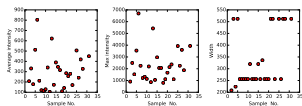


FIGURE – Plots of different attributes of the data set

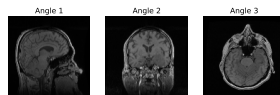


FIGURE – Viewing angles of MRI scan



Pre-processing

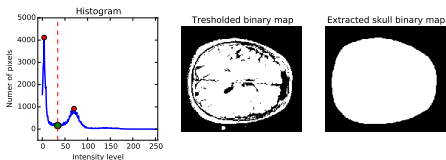


FIGURE – Process of skull extraction

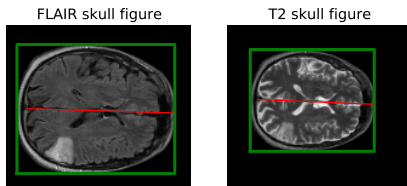


FIGURE – Skulls properties in FLAIR and T2



Pre-processing

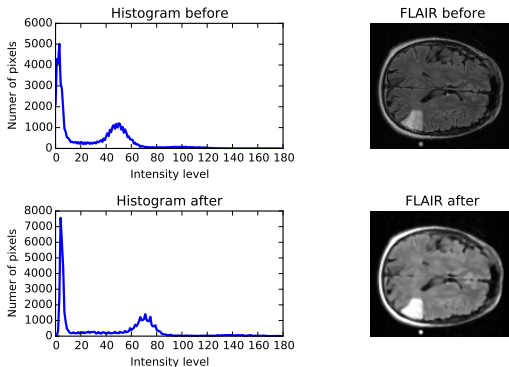


FIGURE – Median filter effect on image histogram



Segmentation - K-Means

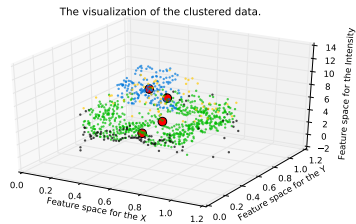
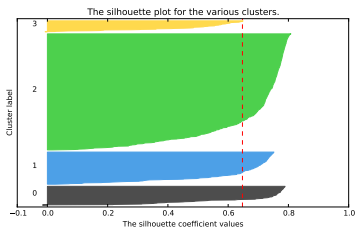


FIGURE – Silhouette analysis for K-Means(k=5)



Segmentation - Combined

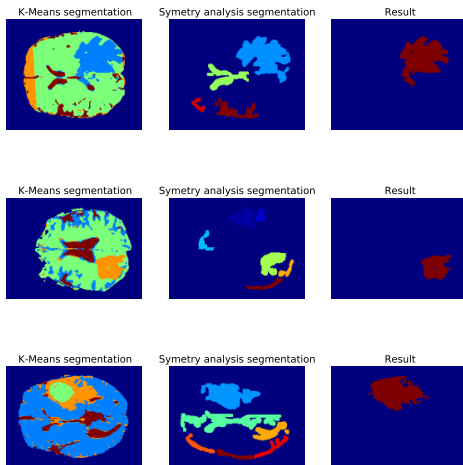


FIGURE – Segmentation with results



Segmentation - Alternatives

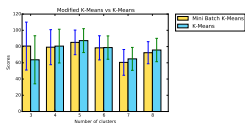


FIGURE – Mini K-Means

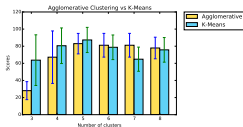


FIGURE – Agglomerative clustering

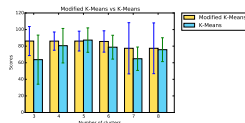


FIGURE – K-Means with position



Classification

Tested methods

- Feature extraction & evaluation
- Texture features extraction with Gray-Level Co-Occurrence Matrix
- Texture features extraction with Local Binary Pattern

Classification algorithms

- SVM (Support vector machine)
- Gaussian Naive Bayes
- Logistic Regression
- Random Forest



Classification - Feature extraction & evaluation

Selected features (out of 59)

- Tumor volume (in mm^3)
- Tumor position (x,y,z) calculated from the middle of the brain
- Metrics intensity of tumor area
- 8 bins of intensity histogram

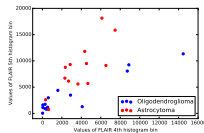


FIGURE – Selected features extracted from data set




FIGURE – Tumor positional features



Classification - Texture features extraction with GLCM & LBP

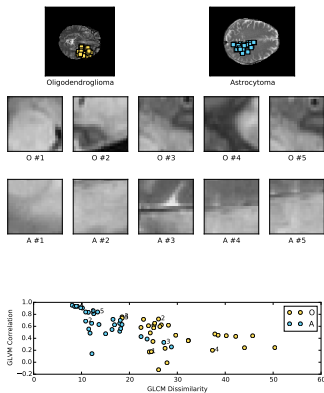


FIGURE – Co-occurrence matrix features for Oligodendroglioma and Astrocytoma



Radiology imaging

Tumor segmentation

METHOD	BEST SCORE
Mini Batch K-Means (5 clusters)	89.027% (std : 5.408)
K-Means (5 clusters)	88.168% (std : 5.264)
K-Means with position (5 clusters)	86.026% (std : 5.282)
Agglomerative Clustering	88.956% (std : 10.632)

Cancer classification

METHOD	BEST SCORE
Random Forest Classifier	87.000% (std : 12.991)
Logistic Regression	81.297% (std : 5.744)
Logistic Regression (texture)	68.285% (std : 0.082)



Combined Radiology and Pathology

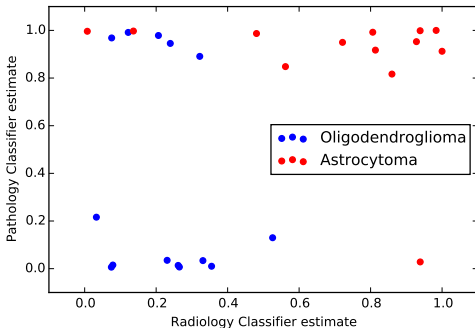


FIGURE – Comparison of Pathology and Radiology results (average estimations of Oligodendroglioma cancer for each sample)



Results

Conclusion

- Random Forest classifier validated with k-fold cross validation had average accuracy of 87.0%
- Pre-processing of the input data is a hand-crafted process, that had to be performed
- K-Means had the best score out of Mini Batch K-Means, K-Means with modified input vector (with position), and Agglomerative clustering



Combined Radiology and Pathology Classification of Brain Tumors

Rozpoznanie guza mózgu na podstawie obrazu radiologicznego i patologicznego

Piotr Giedziun

Supervisor:
dr hab. inż. Henryk Maciejewski

4 March 2016

